

[CASE REPORT]

Parkinsonism Relating to Intoxication with Glyphosate

Makoto Eriguchi¹, Kotaro Iida¹, Shuhei Ikeda¹, Manabu Osoegawa², Kenya Nishioka³,
Nobutaka Hattori³, Hiroshi Nagayama⁴ and Hideo Hara¹

Abstract:

We herein report the case of a 38-year-old man who developed parkinsonism 4 years after ingesting glyphosate. The patient presented with right-sided bradykinesia and cogwheel rigidity without autonomic symptoms. Magnetic resonance imaging of the brain and [¹²³I]-metaiodobenzylguanidine myocardial scintigraphy were normal. A drastic response to levodopa and the presence of levodopa-induced dyskinesia without strong non-motor symptoms were seen in this patient. We considered that young-onset atypical parkinsonism was associated with a history of sublethal glyphosate ingestion. Epidemiologic investigations have shown that exposure to pesticides is a risk factor for Parkinson's disease (PD). Our findings support the notion that glyphosate exposure might be related to the onset of PD.

Key words: Parkinson's disease, glyphosate, pesticide

(Intern Med 58: 1935-1938, 2019)

(DOI: 10.2169/internalmedicine.2028-18)

Introduction

Parkinson's disease (PD) is the second most common neurodegenerative disorder after Alzheimer's disease. Symptoms of PD include rigidity, tremor, bradykinesia, and loss of postural reflexes (1). Several reports have mentioned exposure to pesticides as a risk factor for PD (2-5). This hypothesis was suggested by the discovery of neurotoxic effects from a metabolite of 1-methyl-4-phenyl-1,2,3,6-tetrahydropyridine (MPTP), which is converted in the body to a pro-parkinsonian molecule with a structure resembling the herbicide paraquat (6).

Epidemiologically, the risk of developing PD increases with increasing duration of work in agriculture (4). In experimental models, the pesticides paraquat, which causes oxidative stress, and rotenone, which inhibits mitochondrial complex I, both induce loss of nigral dopaminergic neurons and behavioral changes associated with human PD (7).

We herein report a patient presenting with parkinsonism four years after glyphosate ingestion and discuss whether or not glyphosate might be a possible risk factor for parkinsonism.

Case Report

A 38-year-old Japanese man who developed parkinsonism 4 years after glyphosate poisoning came to our clinic. He had no family history of neurologic disorders. He had started operating a farm growing strawberries nine years earlier. At age 34, he attempted suicide by taking 200 mL glyphosate; he vomited after 10 minutes. His family took him to the emergency room in Saga University Hospital. His stomach was pumped, and activated carbon was administered. He was discharged the next day without any symptoms or laboratory abnormalities. Four years later, he noticed right-handed clumsiness and gait disturbance and was referred to the department of neurology. He did not take any drugs that might have triggered parkinsonism, including antipsychotics and antidepressives. The patient was informed that we wanted to submit his case study for publication and provided his informed consent.

A neurologic examination revealed right-sided hemiparkinsonism, including bradykinesia and cogwheel rigidity, without any autonomic symptoms, such as constipation or orthostatic faintness. The results of the head-up tilt test (HUT) were within normal limits. The blood pressure and

¹Division of Neurology, Department of Internal Medicine, Saga University Faculty of Medicine, Japan, ²Osoegawa Neurology clinic, Japan, ³Department of Neurology, Juntendo University, Japan and ⁴Graduate School of Medicine, Nippon Medical School, Japan

Received: August 27, 2018; Accepted: December 17, 2018; Advance Publication by J-STAGE: February 25, 2019

Correspondence to Dr. Makoto Eriguchi, eriguchm@cc.saga-u.ac.jp

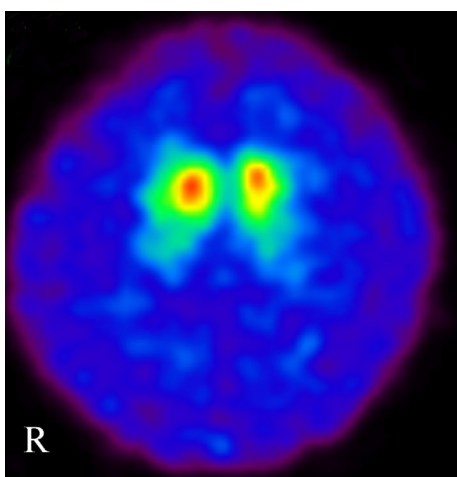


Figure. Results of [^{123}I]-ioflupane single photon emission computed tomography show laterality with accumulation decreased on the left side compared with the right side (specific binding ratio right 6.22, left 5.43).

heart rate in the dorsal position (5 minutes after 70°HUT) were 121/73 (138/84) mmHg and 63 (85) beats/min, respectively. Coefficients of variation of RR intervals in the resting state and during deep breathing were 2.91% and 7.83%, respectively, which were slightly below the normal respective ranges. The patient showed no urinary symptoms, including urinary frequency or feelings of residual urine. His cognitive function was normal with a full score on the Mini-Mental State Examination.

Because he had history of a suicide attempt, we interviewed him in detail on his mental status. Results showed a stable mental status with no symptoms of depression. There are no items on the Japanese version of the REM sleep behavior disorder screening questionnaire, a specific screening scale for assessment of REM sleep behavior disorder. We therefore checked his sense of smell using an intravenous olfactometry test, which showed a slightly abnormal olfactory function with a latency of 15 seconds (cut-off <10 seconds) and continuing time of 43 seconds (cut off >70 seconds). The patient had smoked 10 cigarettes a day for 20 years. Hypofunction of smell can be caused by both Parkinson disease as well as smoking (8). We did not consider the decrease in his olfactory sensitivity as being significant to the findings related to parkinsonism. We also concluded that he did not show non-motor symptoms of PD.

Magnetic resonance imaging (MRI) of the brain and [$^{99\text{m}}\text{Tc}$]-ethyl cysteinyl dimer single-photon emission computed tomography ($^{99\text{m}}\text{Tc}$ -ECD SPECT) showed no abnormalities. Likewise, [^{123}I]-metaiodobenzylguanidine (MIBG) myocardial scintigraphy revealed no abnormalities. The heart-to-mediastinum uptake ratio (H/M) was 2.17 in the early stage and 2.0 in the delayed stage [cut-off H/M of early stage ≤ 2.04 (9)], but [^{123}I]-ioflupane SPECT showed the lateralized accumulation (Figure). All tested hematologic and biochemical parameters were within normal limits. Genetic screening relating to familial PD revealed no patho-

genic mutations [*synuclein alpha (SNCA)* multiplications, exon 21, 31, and 41 in *leucine-rich repeat kinase 2 (LRRK2)*, full exons of *parkin RBR E3 ubiquitin protein ligase (PRKN)*, *PTEN-induced putative kinase 1 (PINK1)*, or *GTP cyclohydrolase 1 (GCH1)*]. Levodopa carbidopa was started and increased to a dose of 600 mg per day, after which his symptoms of parkinsonism improved from a score of 16 on the Unified Parkinson's Disease Rating Scale Part III to a score of 0. However, levodopa-induced dyskinesia was observed. Levodopa carbidopa 300 mg and ropinirol 8 mg yielded a good clinical course without any impact on the patient's daily life.

Discussion

We herein report the case of a patient who developed parkinsonism four years after glyphosate ingestion. The characteristics of our patient were bradykinesia and rigidity along with a drastic response to levodopa and the presence of levodopa-induced dyskinesia in the absence of common non-motor symptoms. The symptoms of our patient did not meet the standard criteria of PD (1).

Epidemiologic investigations have provided substantial evidence supporting the notion that pesticides are a risk factor for PD (2). To date, rotenone, which inhibits mitochondrial complex I, and paraquat, which causes oxidative stress, have been linked experimentally to pathophysiologic mechanisms implicated in human PD (7). Groups of pesticides linked to the mechanisms of mitochondrial dysfunction or oxidative stress have also been shown to be associated with PD (3), expanding on experimental studies to provide evidence that these mechanisms play a role in PD in humans.

However, little is known about glyphosate-induced parkinsonism. Glyphosate is commonly used worldwide in agriculture. It acts primarily through the inhibition of the shikimate metabolic pathway in plants. Because this pathway is absent in mammals, glyphosate is considered to be of low toxicity to humans. However, the ingestion of commercial formulations of glyphosate-surfactant herbicide have been associated with various toxic effects, including gastrointestinal injury, laryngeal injury, an impaired renal function, metabolic acidosis, arrhythmias, pulmonary toxicity, shock, and even death (10).

Glyphosate-induced parkinsonism is rare, but three additional case reports exist (Table) (11-13). Two patients experienced accidental skin exposure (11, 13), and one patient had chronic occupational exposure for over three years (12). The present report is the first to describe a possible effect of oral ingestion of glyphosate. Levodopa improved the symptoms of two of these patients (11, 12) as well as the present patient. T2-weighted brain MRI revealed hyperintensity in the basal ganglia and midbrain of one patient (11) and bilateral hypointense lesions in the globus pallidus in another (12), suggesting secondary parkinsonism. However, brain MRI revealed normal findings in the present case as well as in one other case (13). Our patient had a low density

Table. Findings of a Literature Review Compared with the Present Patient.

Case No.	Reference No.	Age at onset	Sex	Nature of exposure	Elapsed time between exposure and symptom onset	Motor symptoms	Other symptoms	Brain MRI findings
1	11	54	Male	Spray	1 month	Symmetrical Parkinsonism	None	Hyperintensity on T2WI from substantia nigra to basal ganglia
2	12	44	Female	Occupational	3 months	Resting tremor, akinesia, rigidity in all limbs	None	Bilateral hypointensity in globus pallidus on SWI
3	13	58	Female	Spray	1 week	Mask face, bradykinesia, cogwheel rigidity in all limbs	None	Normal
Current case		38	Male	Oral Ingestion	4 years	Bradykinesia, right side dominant cogwheel rigidity	None	Normal

SWI: susceptibility weighted imaging, T2WI: T2 weighted imaging

of dopamine transporters in the striatum, which suggested a loss of dopaminergic neurons similar to that found in sporadic PD. However, MIBG myocardial scintigraphy findings remained normal, and our patient did not have dysautonomia. These findings support our notion that glyphosate-induced PD directly disturbed dopaminergic neurons via a mechanism that differed from the accumulation of alpha-synuclein. An experimental study showed that endogenous α -synuclein levels in the SH-SY5Y neuroblastoma cell line were markedly increased by paraquat, and to a lesser extent by rotenone and maneb, but not by glyphosate (14). The mechanism by which glyphosate leads to parkinsonism is presumed to differ from the mechanism of PD, in which α -synuclein deposits are noted in the central nervous system and on peripheral nerves.

Some reports suggest that glyphosate may lead to parkinsonism via central nervous system injury (15-17). Glyphosate is an herbicide derived from glycine, and the neurotoxic effects of glycine include the inhibition of neurotransmitters and activities as a permissive cofactor for the activation of N-methyl-D-aspartate (NMDA) receptors. The hyperactivation of NMDA receptors is thought to produce neurotoxic effects (15). *In vitro* experiments have shown that glyphosate activates the apoptotic process and induces cell death by phagocytosis (16). Others have suggested that glyphosate provokes neurodegeneration in gamma-aminobutyric acid and dopamine neurons (17).

One report from Taiwan examined 2,023 individuals who had ingested glyphosate but focused only on the immediate effects of glyphosate and not the delayed effects (10). Only our patient developed symptoms four years after ingesting glyphosate; the other three cases developed symptoms at 1 week to 3 months after glyphosate exposure (Table). There-

fore, this is the first report of the delayed effects of glyphosate ingestion.

One of the limitations of this case report is that we were unable to strictly exclude the possible co-occurrence of young-onset PD and glyphosate exposure. However, in the present case, the potential epidemiologic evidence and young-onset of atypical parkinsonism with a history of ingesting a sublethal amount of glyphosate indicated that glyphosate was related to the onset of PD in this patient. Furthermore, previous reports (15-17) and our present findings suggest the possibility of glyphosate-induced parkinsonism, including early onset parkinsonism, levodopa-responsive parkinsonism without autonomic symptoms, and pathophysiologic symptoms unrelated to α -synuclein.

Worldwide, glyphosate is commonly used to control weeds. However, its neurotoxic effects and influences on the nervous system remain unclear. We encountered a patient who presented with levodopa-responsive parkinsonism four years after glyphosate ingestion. Further studies are needed to clarify the relationship between glyphosate exposure and the onset of PD.

The authors state that they have no Conflict of Interest (COI).

References

1. Postuma RB, Berg D, Stern M, et al. MDS clinical diagnostic criteria for Parkinson's disease. *Mov Disord* **30**: 1591-1601, 2015.
2. Ascherio A, Schwarzschild MA. The epidemiology of Parkinson's disease: risk factors and prevention. *Lancet Neurol* **15**: 1257-1272, 2016.
3. Tanner CM, Kamel F, Ross GW, et al. Rotenone, paraquat, and Parkinson's disease. *Environ Health Perspect* **119**: 866-872, 2011.
4. Petrovitch H, Ross GW, Abbott RD, et al. Plantation work and

- risk of Parkinson disease in a population-based longitudinal study. *Arch Neurol* **59**: 1787-1792, 2002.
5. Baldi I, Cantagrel A, Lebaillly P, et al. Association between Parkinson's disease and exposure to pesticides in southwestern France. *Neuroepidemiology* **22**: 305-310, 2003.
 6. Langston JW, Ballard P, Tetrud JW, Irwin I. Chronic Parkinsonism in humans due to a product of meperidine-analog synthesis. *Science* **219**: 979-980, 1983.
 7. Henchcliffe C, Beal MF. Mitochondrial biology and oxidative stress in Parkinson disease pathogenesis. *Nat Clin Pract Neurol* **4**: 600-609, 2008.
 8. Ajmani GS, Suh HH, Wroblewski KE, et al. Smoking and olfactory dysfunction: a systematic literature review and meta-analysis. *Laryngoscope* **127**: 1753-1761, 2017.
 9. Sawada H, Oeda T, Yamamoto K, et al. Diagnostic accuracy of cardiac metaiodobenzylguanidine scintigraphy in Parkinson disease. *Eur J Neurol* **16**: 174-182, 2009.
 10. Chen YJ, Wu ML, Deng JF, Yang CC. The epidemiology of glyphosate-surfactant herbicide poisoning in Taiwan, 1986-2007: a poison center study. *Clin Toxicol (Phila)* **47**: 670-677, 2009.
 11. Barbosa ER, Leiros da Costa MD, Bacheschi LA, Scaff M, Leite CC. Parkinsonism after glycine-derivate exposure. *Mov Disord* **16**: 565-568, 2001.
 12. Wang G, Fan XN, Tan YY, Cheng Q, Chen SD. Parkinsonism after chronic occupational exposure to glyphosate. *Parkinsonism Relat Disord* **17**: 486-487, 2011.
 13. Zheng Q, Yin J, Zhu L, Jiao L, Xu Z. Reversible Parkinsonism induced by acute exposure glyphosate. *Parkinsonism Relat Disord* **50**: 121, 2018.
 14. Chorfa A, Betemps D, Morignat E, et al. Specific pesticide-dependent increases in alpha-synuclein levels in human neuroblastoma (SH-SY5Y) and melanoma (SK-MEL-2) cell lines. *Toxicol Sci* **133**: 289-297, 2013.
 15. Dannhardt G, Kohl BK. The glycine site on the NMDA receptor: structure-activity relationships and therapeutic applications. *Curr Med Chem* **5**: 253-263, 1998.
 16. Gui YX, Fan XN, Wang HM, Wang G, Chen SD. Glyphosate induced cell death through apoptotic and autophagic mechanisms. *Neurotoxicol Teratol* **34**: 344-349, 2012.
 17. Negga R, Stuart JA, Machen ML, et al. Exposure to glyphosate-and/or Mn/Zn-ethylene-bis-dithiocarbamate-containing pesticides leads to degeneration of gamma-aminobutyric acid and dopamine neurons in *Caenorhabditis elegans*. *Neurotox Res* **21**: 281-290, 2012.

The Internal Medicine is an Open Access journal distributed under the Creative Commons Attribution-NonCommercial-NoDerivatives 4.0 International License. To view the details of this license, please visit (<https://creativecommons.org/licenses/by-nc-nd/4.0/>).